

Diagnosis and Treatment of First Metatarsophalangeal Joint Disorders.

Section 6: Other Disorders

Clinical Practice Guideline First Metatarsophalangeal Joint Disorders Panel:
John V. Vanore, DPM,¹ Jeffrey C. Christensen, DPM,² Steven R. Kravitz, DPM,³
John M. Schuberth, DPM,⁴ James L. Thomas, DPM,⁵ Lowell Scott Weil, DPM,⁶
Howard J. Zlotoff, DPM,⁷ and Susan D. Couture⁸

This clinical practice guideline (CPG) is based upon consensus of current clinical practice and review of the clinical literature. The guideline was developed by the Clinical Practice Guideline First Metatarsophalangeal (MTP) Joint Disorders Panel of the American College of Foot and Ankle Surgeons. The guideline and references annotate each node of the corresponding pathways.

Other Disorders of the First MTP Joint (Pathway 7)

Many additional, although less common, disorders exist that may produce first MTP joint pathology (Fig. 1). These include various arthritides (1), especially gouty arthritis (2–5). Other causes include infection (6,7), tumors (osseous or soft tissue) (8–10), vascular and neurologic abnormalities (11–13), and the complex pathologies associated with the diabetic foot (14).

Significant History (Node 1)

Patients may present with acute or chronic joint pain. A complete medical history is indicated to rule out systemic disorders (eg, diabetes or past gout attacks).

Significant Findings (Node 2)

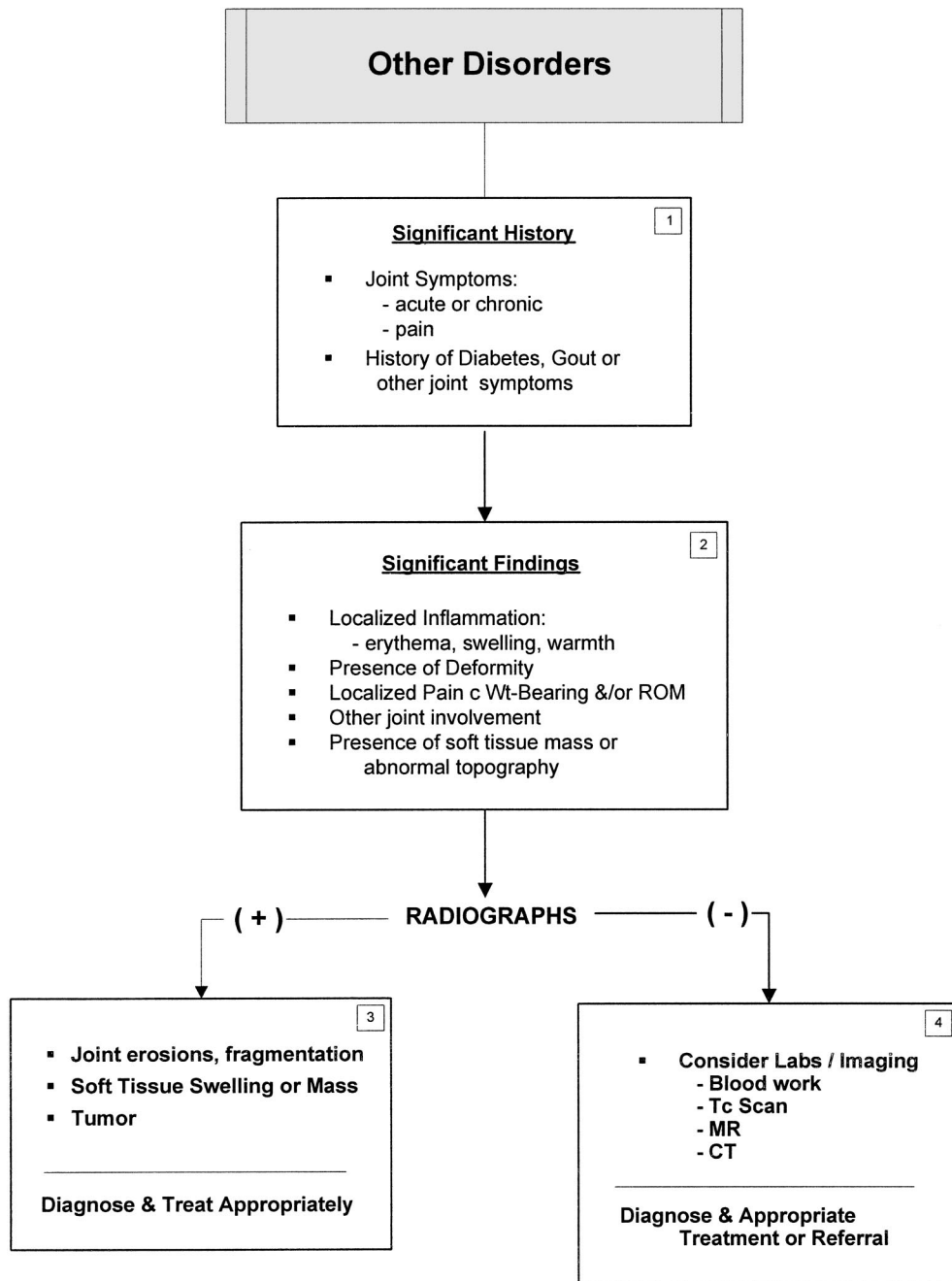
Edema, discoloration, and/or increased warmth may be present. Other joints may also be affected. Localized pain with weightbearing or on range of motion may be seen, as well as the presence of a soft-tissue mass or an abnormal topography.

¹ Chair, Gadsden, AL; ² Everett, WA; ³ Richboro, PA; ⁴ San Francisco, CA; ⁵ Board Liaison, Birmingham, AL; ⁶ Des Plaines, IL; ⁷ Camp Hill, PA; and ⁸ Park Ridge, IL. Address correspondence to: John V. Vanore, DPM, Gadsden Foot Clinic, 306 South 4th St, Gadsden, AL 35901; e-mail: jvanore@prodigy.net

Copyright © 2003 by the American College of Foot and Ankle Surgeons
1067-2516/03/4203-0007\$30.00/0
doi:10.1053/jfas.2003.50041

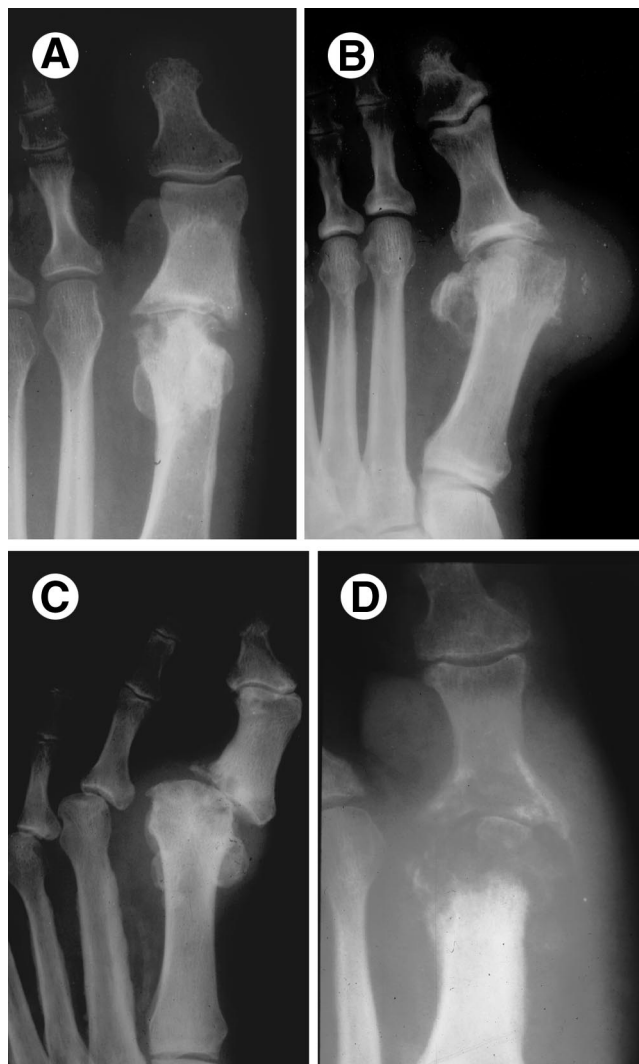

FIGURE 1 Radiographic evaluation is often useful in the diagnosis of a variety of other first MTP joint disorders. These may include a diverse group of acute to chronic pathology, including (A) avascular necrosis, (B) gout, (C) neuropathic arthropathy, and (D) osteomyelitis.



Pathway 7

Radiographic Examination

Radiographic examination should be undertaken as a general diagnostic tool (1) (Fig. 1).

Radiographs: positive radiographic findings (Node 3). These may include joint erosions, fragmentation, or tumor. Soft tissue swelling or a mass may be identified. A working diagnosis should be established and proper treatment and/or referral initiated.

Radiographs: negative radiographic findings (Node 4). If radiographs are negative, further evaluation is indicated.

Laboratory testing and further imaging studies such as technetium scan, magnetic resonance imaging, and computed tomography may be considered. Once a diagnosis is established, treatment and/or proper referral may be considered.

Summary

Systemic, metabolic, and other unusual pathologies may occur and need to be considered in the patient who presents with first MTP joint symptoms.

References

1. Stiles RG, Carpenter WA, Resnick D. Radiographic manifestations of arthritides involving the foot. In *Musculoskeletal Disorders of the Lower Extremities*, pp 307–321, edited by LM Oloff, WB Saunders, Philadelphia, 1994.
2. Hamilton EB. Painful feet. *Br Med J* 1:342–344, 1969.
3. Mertz DP. Hallux rigidus arthrosis and gout. *Fortschr Med* 100:446–448, 1982.
4. Weinfeld SB, Schon LC. Hallux metatarsophalangeal arthritis. *Clin Orthop* 349:9–19, 1998.
5. Dabdoub WH, Short LA, Gudas CJ. Acute gouty arthritis in a first metatarsophalangeal joint replaced with a flexible-hinge implant: a case report. *J Foot Surg* 20:167–169, 1981.
6. Rahn KA, Jacobson FS. Pseudomonas osteomyelitis of the metatarsal sesamoid bones. *Am J Orthop* 26:365–367, 1997.
7. George DH. Management of hyperkeratotic lesions in the elderly patient. *Clin Podiatr Med Surg* 10:69–77, 1993.
8. Wu KK. Phalangeal periosteal (juxtacortical)chondroma of the foot. *J Foot Surg* 31:527–529, 1992.
9. Kramer KL, Winter M. Osteochondroma as an unusual cause of metatarsus primus varus. *Z Orthop Ihre Grenzgeb* 127:22–24, 1989.
10. Caspi I, Friedman B, Horoszovski H. Tumoral calcinosis simulating osteomyelitis. *J Foot Surg* 28:547–548, 1989.
11. Milgram JW. Osteomyelitis in the foot and ankle associated with diabetes mellitus. *Clin Orthop* 296:50–57, 1993.
12. Giacalone VF, Krych SM, Harkless LB. The University of Texas Health Science Center at San Antonio: experience with foot surgery in diabetics. *J Foot Ankle Surg* 33:590–597, 1994.
13. Jacobs RL. The diabetic foot. In *Disorders of the Foot and Ankle*, pp 1908–1936, edited by M Jahss, WB Saunders, Philadelphia, 1991.
14. Kerr R, Sartoris DJ, Fix CF, Resnick D. Imaging of the diabetic foot. In *The High Risk Foot in Diabetes Mellitus*, pp 79–102, edited by RG Frykberg, Churchill Livingstone, New York, 1991.